

APPENDIX 13

HUMAN SKELETAL REMAINS

C Harding

Methodology

The articulated skeletons and disarticulated bones were analysed using standard osteological techniques (Buikstra and Ubelaker 1994). The bones ranged from a well-preserved articulated skeleton to poorly preserved single bones. Where preservation allowed, the skeletons was assessed for age, sex, stature, non-metric traits, and pathology. There is an inherent problem with almost all the techniques used to analyse skeletal material from archaeological sites (Molleson and Cox 1993), in that the populations used for the development of methodology usually date from a different period to the sample, and may even be of a different ethnic group (Hunter *et al* 1996). However, any potential inaccuracies are accepted as falling within acceptable limits.

The presence, or absence, of all skeletal and dental elements was recorded for each skeleton (or context, if the bones were disarticulated). All bones were attributed to the left or right if possible and, if necessary, fragmentary crania were temporarily reconstructed and loose teeth returned to their sockets.

The skeletal material was sexed using as many as possible of the 23 cranial and 20 pelvic sexing criteria described by Schwartz (1995). Using these criteria, the sex of a complete, well-preserved skeleton can be up to 98% accurate (Hunter *et al* 1996), and as is obvious, the greater the number of criteria employed, the more accurate the result will be. No single criterion gives a 100% accurate result, but the pelvis is the most reliable bone for sexing. Nearly all criteria rely on the secondary characteristics of sexual dimorphism (the generalised differences between men and women). Such characteristics develop around puberty, making sexing of sub-adults (below 17 years of age) extremely inaccurate; indeed, Bass writes (1995, 25) that ‘the question still arises as to whether sub-adult skeletal material can be accurately sexed, but the consensus is that any determination is little better than a guess’. Sub-adults have been sexed using the crown height of the permanent mandibular canine (White 1988), but,

obviously, this technique relies on the infant having developed permanent teeth, and the teeth being present. Sub-adults can also be sexed using DNA (Stone *et al* 1996), though at the time of writing, this technique was too expensive to be used routinely, and the sub-adults from the northern Lanes were not sexed.

The age estimation of the skeletons was divided into two categories: adult and sub-adult. These categories were also subdivided following Roberts (1997; Table 56). Many techniques are used to age individuals, but none provides an entirely accurate chronological age, as all of the procedures produce age ranges within which an individual might be placed (Schwartz 1995). Some methods are more accurate than others, but, as no technique is perfect, the results from as many methods as possible are combined, in order to establish as accurate an age range as possible. Most of the ageing techniques for adults use the cranium or the pelvis, and the differing preservation of individual skeletons greatly affects the number of methods that can be used.

The processes used to age adult skeletons are dental attrition (Miles 1963), changes to the pubic symphysis of the pelvis (Brooks and Suchey 1990) and auricular surface of the pelvis (Lovejoy *et al* 1985), and cranial suture closure (Meindl and Lovejoy 1985). Thus, if

Sub-adults	
Foetus	Under 40 weeks
Neonate	Birth - 1 month
Infant	1 - 12 months
Juvenile 1	1 - 4 yrs
Juvenile 2	5 - 8 yrs
Juvenile 3	9 - 12 yrs
Adolescent	13 - 17 yrs
Adults	
Young Adult	18 - 25 yrs
Young Middle Adult	26 - 35 yrs
Older Middle Adult	36 - 45 yrs
Mature Adult	46+ yrs

Table 56: Age divisions of human skeletons

both cranium and pelvis are damaged or missing, age estimation can be difficult. If none of the above methods can be implemented, the fusion of the epiphyses of skeletal elements, such as the late-fusing sternal clavicles, may be used to assess whether or not the skeleton is that of an adult. Some criteria for ageing, such as changes of the pubic symphysis, vary according to sex. Thus the skeleton should be sexed before age estimation is undertaken.

Sub-adults can be aged more accurately than adults, although there is a margin of error of up to several years for adolescents, depending on the number of techniques used (Buikstra and Ubelaker 1994). The sub-adults at the northern Lanes were aged mainly by using long-bone length (Scheuer *et al* 1980), but dental development (Ubelaker 1989) and epiphyseal fusion (Workshop of European Anthropologists 1980) were also used.

Preservation

The preservation of the bone is divided into categories, based mainly on the percentage of bones that survive (Table 57). Poor survival of the surface of the bone or extreme fragmentation of the skeleton will reduce the category by one level. If the skeleton is in a poor or very poor condition, but there are several complete long bones, and joint surfaces, or the skull or the pelvis, survive, the preservation category may be increased by one level.

Stature

Estimation of the stature of adults is based on the length of long bones (Hunter *et al* 1996). For very complete skeletons, the most accurate technique to estimate height is ‘Fully’s Anatomical Method’, which calculates stature using measurements of all the bones that contribute to a person’s height (such as feet, legs, vertebrae, and skull; Fully 1956). This method can rarely be used on archaeological material, however, because skeletons are seldom complete, and a second technique, developed by Trotter (1970), is normally used. The maximum expected stature of an individual can be calculated using a regression equation based on long-bone length, the equation varying according to the sex of an individual and the bone that is used. Measurements of leg bones (particularly if the tibia

Survival	Preservation
Under 10%	very poor
10-25%	poor
25-50%	fair
50-75%	good
75-90%	very good
Over 90%	excellent

Table 57: Levels of preservation of human skeletons

and femur measurements are combined) produce a smaller standard error than arm bones.

Post-cranial non-metric traits

Non-metric traits are discrete, quasi-continuous or epigenetic morphological traits, identifiable in skeletons, that have environmental, genetic, or unknown causes (Chamberlain 1996). These are used to compare the genetic distance between different populations. Although non-metric traits in this assemblage were recorded where possible, the results have not been analysed, as the sample size was too small to produce statistically valid results.

Metrical data

Measurements of bones may be used to interpret skeletal shape. These features may indicate different ethnic groups or reflect lifestyle. Measurements of bones (apart from stature estimates) have little value except to make comparisons between populations (Schwartz 1995). As the sample size is too small to produce an accurate reflection of the population, these measurements were not taken.

Minimum number of individuals (MNI)

Normally, all the different bones and bone fragments of individuals from a skeletal population are counted and the minimum number of individuals represented within the assemblage estimated. However, as, in this case, many of the bones were scattered over a large area, it would be inaccurate to suggest that they were associated. Therefore, all bones from different contexts have been treated as separate individuals, unless other factors suggested otherwise. A minimum number of individuals was established by using the most frequently occurring skeletal element.

Health and disease

Each individual bone has been recorded macroscopically for the presence of any abnormality that might suggest trauma or disease. As the number of skeletons is so small, it would be highly misleading to identify the percentages of individuals affected by different conditions. Therefore, the data were simply categorised and described.

Catalogue

In the interest of brevity, the following abbreviations have been employed in the catalogue for dentition:

Max	Maxilla
Man	Mandible
R/L	Right/left
±	Present
D	Dental Enamel Hypoplasia present

Calculus:

A All sides
F Fleck
/ Socket
B Buccal
S Slight
A Absent
M Mesial
ME Medium
MU Multiple

HB1 *State:* articulated skeleton.
Preservation: very good.
Age: old middle adult.
Sex: male.
Stature: 1744 ± 29.9 mm (5 feet 8½ inches).
Dentition: Dental enamel hypoplasia and slight to medium calculus on most teeth (Brothwell 1981).
Pathology: multiple fractures including depressed pond fractures of the cranium. There is no evidence for healing. There is also a cyst-like lesion on the posterior area of the left ulna head. There are two faint Schmorl's nodes on the vertebrae and slight osteoarthritis of the spine. A lesion, approximately 20 mm in length, is present on the left internal surface on the mandible, which is probably a well-defined area of remodelled osteitis. There is well-remodelled bilateral periostitis on the tibiae.
LAL D 232, fill of well 226, Period 11D

HB2 *State:* articulated skeleton.
Preservation: fair.
Age: neonate.
Sex: not possible to ascertain.
Stature: not possible to estimate.
Dentition: none.
Pathology: none.
KLA D 145, fill of grave 146, in R1 of Building 2000, Period 11A

HB3 *State:* articulated skeleton.
Preservation: very poor.
Age: sub-adult (probably juvenile).
Stature: not possible to estimate.

Sex: not possible to ascertain.

Dentition: none.

Pathology: none.

KLA C 935, external soil, south of Building 2000, Period 11D-12

HB4 *State:* articulated skeleton.
Preservation: fair.
Age: neonate.
Sex: not possible to ascertain.
Stature: not possible to estimate.
Dentition: none.

Pathology: none.

General Comments: although the bones are from two different contexts, the age estimates produced by measurements of them are all the same, and it is, therefore, highly likely that they are all from one individual.

KLAD 37/76, the clay floor of Structure 594 and a soil deposit directly above, Period 11B-11C

HB5 *State:* disarticulated material (cranium).
Preservation: poor.
Age: young adult.
Sex: Male.
Stature: not possible to estimate.
Dentition: no dental disease (maxilla only).
Pathology: bilateral healed cribia orbitalia.
LAL C 375.01, fill of gully 387, Period 7

HB6 *State:* disarticulated material (right tibia).
Preservation: very poor.
Age: probably adult.
Sex: not possible to ascertain.
Stature: not possible to estimate.
Dentition: none.
Pathology: very well-remodelled periostitis on tibia shaft.
LAL C 377, external soil deposit, Period 9

HB7 *State:* disarticulated material (cranium).
Preservation: poor.
Age: middle/mature adult.
Sex: male.
Stature: not possible to estimate.
Dentition: Slight calculus (Brothwell 1981)

MAX	CAL HYPO		D	D	D	D	D			MF D	MF D	AS D	AS D	AS D	AS D	AS D	AS D	CAL HYPO	MAX
R		A	7	6	5	4	3	/	/	1	2	3	4	5	6	7	8		L
R		8	7	6	5	4	3	2	1	1	2	3	4	5	6	7	8		L
MAN	HYPO CAL	D AS	D AS	D AS	D AME	D AME	D AME	D A ME	D AME	D A ME	D AME	D AME	D A ME	D AME	D BS	D AS	D AS	HYPO CAL	MAN

HB1 Dentition

MAX	R	/	7	6	/	/	/	/	/	/	/	/	/	/	6	7	/	L	MAX
-----	---	---	---	---	---	---	---	---	---	---	---	---	---	---	---	---	---	---	-----

HB5 Dentition

MAX	CAL HYPO			MU S D	MU S D	MU S D	MU S D							MU S D	MU S D		MU S	CAL HYPO	MAX
R		/	7	6	5	4	3	/	/	/	/	/	/	5	6	/	/		L

HB7 Dentition

and dental enamel hypoplasia.
Pathology: fracture of right parietal, possibly due to peri-mortem trauma; this shows no signs of healing.
 KLA A 1031.04, fill of pit 1073, Period 8B

HB8 **State:** disarticulated material (left femur).
Preservation: very poor.
Age: adult.
Sex: not possible to ascertain.
Stature: not possible to estimate.
Dentition: none.
Pathology: none.
 KLA A 1055, fill of pit 1069, Period 8B

HB9 **State:** disarticulated material (left scapula).
Preservation: very poor.
Age: adult (probably middle or mature adult).
Sex: not possible to ascertain.
Stature: not possible to estimate.
Dentition: none.
Pathology: none.
 KLA D 456.03, fill of pit 574, Period 8B

HB10 **State:** disarticulated material (left ilium).
Preservation: poor.
Age: old middle adult.
Sex: probably female.
Stature: not possible to estimate.
Dentition: none.
Pathology: none.
General Comments: the ilium has been chewed by a canine.
 KLA C 1050, external surface, Period 11C

HB11 **State:** disarticulated material (left femur).
Preservation: very poor.
Age: probably adult.
Sex: not possible to ascertain.
Stature: not possible to estimate.
Dentition: none.
Pathology: none.
 KLA E 51, fill of ditch 50, Period 9

HB12 **State:** disarticulated material (cranium fragment).
Preservation: very poor.
Age: not possible to estimate.
Sex: not possible to ascertain.
Stature: not possible to estimate.
Dentition: none.
Pathology: none.
 LAL D 901, soil deposit in Building 1564, Period 10C

HB13 **State:** disarticulated material (left femur).
Preservation: very poor.
Age: probably adult.
Sex: not possible to ascertain.
Stature: not possible to estimate.
Dentition: none.

Pathology: very well-remodelled periostitis on anterior and posterior shaft of left femur.
 LAL D 937, make-up deposit for a metallated path east of Building 1564, Period 10C

HB14 **State:** disarticulated material (left humerus).
Preservation: very poor.
Age: adult.
Sex: not possible to ascertain.
Stature: not possible to estimate.
Dentition: none.
Pathology: none.
 LAL D 1013, soil deposit beneath Building 1564, Period 10B

Results

State of preservation

Preservation of the articulated skeletons varied between very poor and very good (Fig 294), whilst the disarticulated material varied between very poor and poor. Although the disarticulated material scored much worse than the articulated skeletons, this was mainly due to their lack of completeness. The condition of most of the bone was good, with no obvious difference between the articulated and disarticulated material.

Minimum number of individuals

The human bones have been taken to represent 14 individuals, four skeletons, and the disarticulated remains of another ten individuals (Table 58). If all the material is counted using repetitions of skeletal elements, however, the minimum number of individuals is reduced to seven, including two neonates, one sub-adult (probably a juvenile), and four adults. The number of neonates was assessed on the left humerus, the sub-adult was identified by the width and shape of the bones, and the adults were assessed by the number of basi-occipital parts of the cranium.

Age determination

The articulated skeletal material contains one old middle adult, two neonates, and a sub-adult (probably

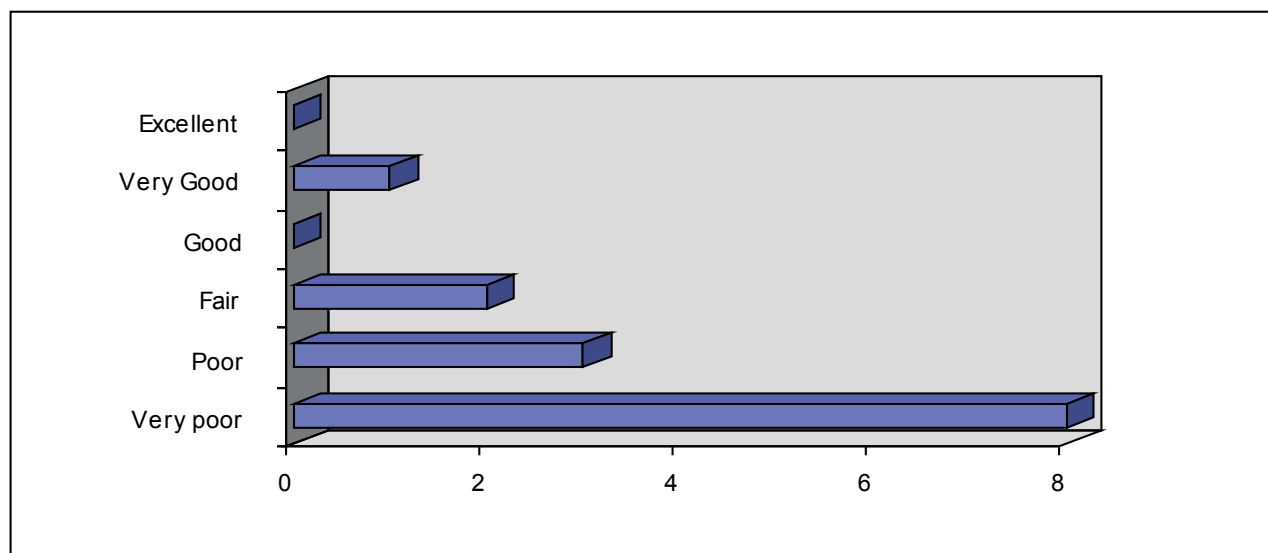


Figure 294: State of preservation of articulated skeletons

	LAL D 232	KLA D 145	LAL D 1013	LAL D 937	LAL C 377	LAL D 901	KLA C 1050	KLA A 1055	KLA E 51	KLA D 456.3	KLA C 935	KLA A 1031.4	LAL C 375.1	KLA D 37/76	Total
Cranium	÷	÷				÷						÷	÷		5
Mandible	÷														1
Maxilla	÷												÷		2
Sternum	÷														1
R Clavicle	÷										÷				2
L Clavicle	÷	÷													2
R Scapula	÷														1
L Scapula	÷									÷					2
R Humerus	÷	÷												÷	3
L Humerus	÷		÷											÷	3
R Ulna	÷														1
L Ulna	÷														1
R Radius	÷	÷													2
L Radius	÷														1
R Ilium	÷														1
L Ilium	÷						÷				÷				3
R Ischium	÷														1
L Ischium	÷														1
R Pubis	÷														1
L Pubis	÷														1
R Femur	÷										÷			÷	3
L Femur	÷	÷		÷				÷	÷		÷			÷	7
R Tibia	÷				÷									÷	3
L Tibia	÷	÷													2
R Calcaneus	÷														1
L Calcaneus	÷														1
Ribs	÷	÷									÷				3
Vertebrae	÷														1
Sacrum	÷														1
Age Group	A	N	A	A	A	A	A	A	A	A	SA	A	A	N	57

A = Adult; N = Neonate; SA = Sub-adult; R = right; L = left

Table 58: Count of skeletal elements

Age	Number
Neonate	2
Infant	0
Juvenile	0
Adolescent	0
Sub-adult (probably juvenile)	1
Young adult	1
Old middle adult	2
Middle/mature adult	1
Mature adult	0
Adult	3
Unknown or possible adult	4
Total	14

Table 59: Age at death of the skeletal material

a juvenile; Table 59). The disarticulated material contained fragments of a young adult, an old middle adult, and a middle/mature adult. There were also three fragments of skeleton that could only be aged as adults, three that were probably adults, and one that it was not possible to age.

The mortality rate for the sample of individuals is relatively evenly distributed between the different age groups. Sub-adults are, however, under-represented, particularly infants and juveniles. As the skeletal material is not part of a cemetery, and therefore not representative of a population, it is not possible to suggest a standard demographic profile for the group.

Sex determination

Only four skeletons could be sexed, three being men and one probably a woman (Table 60). The small number of sexed individuals reflects the very poor state of preservation of most of the skeletal material. The sex ratio is heavily biased towards men but, as it is not a representative cemetery population, it is not appropriate to suggest a reason for this.

Stature

None of the disarticulated material contained complete long bones, and only one adult skeleton (**HB1**) was sufficiently complete to produce a stature estimate. This was estimated using the most accurate bones

Age	Sex
Young adult	Male
Middle adult	Female
Old middle adult	Male
Middle/mature adult	Male

Table 60: The sex of individuals by age

(the femur and the tibia), giving an estimated height of 1744 ± 29.9 mm.

Palaeopathology

There are few signs of disease or ill health in the skeletal material, but it must be noted that, for the most part, this probably reflects the very poor state of preservation of the material examined. Dental health appears to have been quite good, with no dental caries (cavities), abscesses, or signs of periodontal disease seen. Calculus formation can indicate poor dental hygiene (Roberts and Manchester 1995). Only two individuals have any surviving dentition, with both having slight to medium calculus on their teeth, based on the grading system used by Brothwell (1981). Both also had dental enamel hypoplasia, reflected as lines or grooves in the enamel of the teeth resulting from a disruption in enamel formation. This occurs when a developing child undergoes a period of severe stress, for instance an illness, or nutritional deficiencies, often during weaning (Roberts and Manchester 1995).

The most common pathological condition noted was periostitis, a condition by which an inflammation of the membrane surrounding the bone (the periosteum) results in the formation of new bone. Infection can be caused by several factors, which include pathogens spreading to the area, via the circulatory system, from elsewhere in the body, pathogens directly entering the area via an open wound, or a soft-tissue infection, such as an ulcer, which ultimately involves the bone. It is also possible that periostitis may be caused simply by trauma (Roberts and Manchester 1995). It is rarely possible to identify which pathogen caused the inflammation, and therefore periostitis is known as a non-specific infection (*ibid*). **HB6** had very well-healed periostitis on probably the left tibia shaft, of the left femur. The adult man from well 226 (**HB1**) had bilateral periostitis of the tibiae, and an area of osteitis on the mandible. Osteitis is caused by the same biological factors and processes as periostitis, but the infection occurs in the cortex rather than on the surface of the bone (*ibid*).

HB5 had cribra orbitalia (lesions on both orbits of the eye sockets, which are caused by iron-deficiency anaemia). The anaemia could have resulted from a lack of iron in the diet, blood loss due to injury, chronic diseases such as cancer, or parasitic infection of the intestines (*ibid*). It is also the case that cribra orbitalia could be a response to infection, whereby starving the pathogens of necessary iron could stop them surviving and reproducing within the body (Stuart-Macadam 1992).

HB1 exhibits multiple fractures of the cranium, all of which appear to have been inflicted on the individual around the time of death. Injuries to skeletons that

have occurred around the time of death can be recognised by two different indicators: colour and fracture morphology. Archaeological skeletal material is often damaged before and during excavation, and in post-excavation handling, and this can be seen when the new break appears as different in colour from any surface skeletal staining. If, however, the break is stained the same colour as the bone surfaces, it is more likely to have been stained by the same depositional process as the surface, and is thus more likely to have occurred around the time of death (Buikstra and Ubelaker 1994).

Fracture morphology is the second important guide to whether breaks are old or new. All living bone contains collagen, which helps give it flexibility, absorbing and dispersing energy and stresses, such as those caused by trauma. After death, bone loses its collagen content, but the process takes several weeks or months. Thus, bone that has been dead for several months or more (post-mortem), will react differently to bone that is living or only recently dead (peri-mortem). In addition, injuries sustained a few weeks or more before death (ante-mortem) will show signs of healing (*ibid*). It is not possible, however, to distinguish between trauma occurring just before death and those which occurred just after.

Typically, skull fractures occurring long after death have squared breaks at right-angles to the bone surface, whilst peri-mortem breaks are rounded and oblique in angle (*ibid*). The oblique angle of the break results in internal bevelling, *ie* the area of the break is bigger on the internal surface of the skull than on the external surface. In addition, the adherence of fragments of broken bone to the skull is indicative of the presence of soft tissue when the injury occurred (Ortner and Putschar 1981). The edges of peri-mortem breaks are smooth, but post-mortem breaks have a frayed appearance. Ante-mortem and peri-mortem skull injuries may have fractures radiating from the area of impact, as the energy of the blow spread through the skull, following a path of least resistance, for instance, through foramina (*ibid*). Therefore, peri-mortem fractures stop at sutures and other cracks (such as those caused by an earlier blow). On occasion, the energy of the blow may force the sutures open. Only post-mortem fractures can cross sutures and other fractures (*ibid*).

In the case of this individual, there are holes on either side of the skull, both interpreted as depressed pond fractures. That on the left side is approximately 60 x 60 mm and affects parts of the temporal, frontal, and parietal bones; there are no radiating fractures. The hole on the right side of the skull is approximately 40 mm in diameter, and incorporates areas of the frontal and parietal bones. A fragment of bone from

the outer orbit of the eye appears to have sheared off due to pressure exerted on the skull, and there is a fracture running from the edge of the hole as far as the coronal suture. This is probably traumatic in origin. There is a fracture on the left sphenoid, approximately 35 mm long, anterior to the external auditory meatus, and a possible depressed fracture on the right temporal bone. The mandible is fractured at the chin, which may have occurred around the time of death (peri-mortem trauma). The right coronoid process and the left mandibular condyle both show possible signs of peri-mortem trauma. The wounds are very deep and must have been inflicted with great force.

Injuries resulting from sharp-force trauma, such as those caused by a sword or an axe, have a burnished appearance (Knight 1991), which, in this case, none of the fractures showed. Thus, it seems that the deceased was struck in the face, several times, with a blunt instrument, and, as none of the lesions show any indications of healing, this must have happened around the time of death. The deep wounds inflicted on this man must have destroyed much of the facial area. There are no defensive wounds on other parts of the body, for instance a parry fracture of the ulna (Roberts and Manchester 1995), suggesting that the victim did not, or was not able to, defend himself or to fight back. Heads seem often to be the target for interpersonal violence, as the head and brain are vulnerable (Knight 1991, 156). The body was dumped in a well, which may have been out of use, and was covered, probably deliberately, with large quantities of domestic debris (*Ch* 4), including leather shoes and broken pottery. The nature of the injuries and the apparent concealment the body suggest an unnatural death, and it is possible, even likely, that the individual was murdered.

HB1 also had a subchondral cyst of the distal left ulna, and slight osteophyte lipping of a vertebral body, both probably representing early osteoarthritis. Slight osteoarthritis is common in a middle-aged individual of the Roman period. There are two slight Schmorl's nodes, which may be due to stress on the spine (Roberts and Manchester 1995), and also a lesion on the left internal surface of the mandible; approximately 20 mm in length, it is probably an area of healed osteitis. A well-remodelled bilateral periostitis on the tibiae is also visible.

Skull **HB7** shows a fracture of the right parietal, possibly due to peri-mortem trauma. The fracture is approximately 50 mm long, running from a small semi-circular crack in the middle of the parietal to the squamosal suture; the fracture shows no signs of healing. It could have been as a result of a blow to the side of the head, or the person hitting his head during a fall.

Conclusions

The human skeletal remains, all from Roman contexts, are in a very poor state of preservation, with the four articulated skeletons being best preserved. The articulated skeletons were clearly not part of a cemetery group, having been found in a well and inside buildings. The disarticulated material was spread over a large area, the bones apparently randomly

distributed, resulting from effectively random disturbance or importation, and there is no evidence for deliberate selection. It is not impossible that they originated from a disturbed cemetery site, but the small number of bones found in any one context, with the exception of the body in the well, may indicate that the material had been moved more than once. Analysis has suggested a minimum number of only seven individuals and a maximum number of 14. The presence of a probable murder victim is very rare in an archaeological context, and of great interest.